DentalOne Partners & Dr Joseph Krajekian

HOLIDAY CONTINUING EDUCATION

COURSE SPONSOR

straumann

Dental Implant A-Z | Patient Experience | Emotional Intelligence

December 5th, 2018

Cleveland Skating Club

2500 Kemper Rd,
Cleveland, OH 44120

DR. JOSEPH KRAJEKIAN
DENTAL IMPLANTS

KAREN GUZI
PATIENT EXPERIENCE

KIM LANGLEY
EMOTIONAL INTELLIGENCE

MICHAEL MAGE
COMEDIAN / MAGICIAN

1

4:00-4:20 Registration
Cocktails
Doctors and Staff

4:20-5:45 Fundamental of dental implants
Speaker : Dr. Krajekian
Attendees: Doctors and Staff

Dinner Served

6:00-6:30 Patient Experience
Speaker : Karen Guzi from Cleveland Clinic
Attendees: Doctors and Staff

6:30 – 8:00 Emotional Intelligence in the dental Office.
Speaker : Kim Langley
Nationally Renowned Guest Speaker
Doctors and Staff

Awards

DentalWorks

© 2018 Joseph Krajekian DMD, MD

2

8:15 -9:00
Implant Practical Application / Hands on
Speaker: Straumann Rep
Attendees: Doctors
Atrium

8:15 -9:00
OMS Protocols Review Lessons After 1 year
Speaker: Dr Krajekian
Attendees: Staff
Main Dining Room

8:15 -9:00
Hygienist and Dental Implant
Speaker: Joanie Biviano
Attendees: Hygienist
President's Room

Dessert Served

9:00-9:45 World Class Entertainment
Speaker : Michael Mage
Attendees: Doctors and Staff
You don't want to miss this

9:45-10:00 Putting it all Together
Speaker : Dr Krajekian

DentalWorks

© 2018 Joseph Krajekian DMD, MD

3

Outline

- Demographics
- Medical Evaluation
- Implant Pharmacology
- Anatomical Considerations
- Treatment planning consideration
- Sample Cases
- Management of Complications

DentalWorks

© 2018 Joseph Krajekian DMD, MD

4

Patient Demographics

5

Aging Population

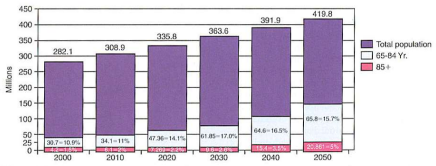

Figure 1-3 By 2050, 20.7% of the population will be older than age 65. In addition to the increasing percentage of 65 year olds, the population is also increasing. As a result, 34.9 million people were older than 65 in 2000, and 86.6 million people will reach this milestone by 2050.

DentalWorks

© 2018 Joseph Krajekian DMD, MD

6

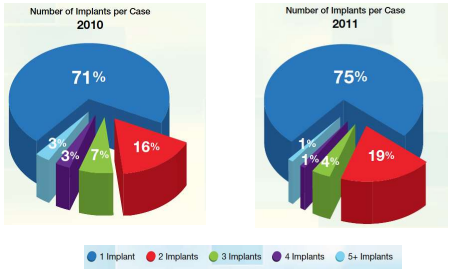

DentalWorks

© 2018 Joseph Krajekian DMD, MD

7

Anatomy of a dental implant

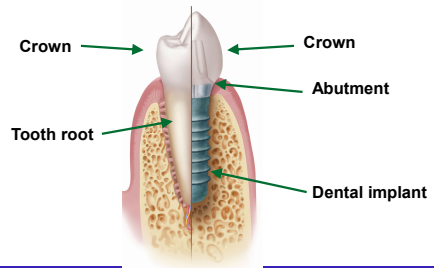

DentalWorks

© 2018 Joseph Krajekian DMD, MD

8

Benefits of dental implants for your patients

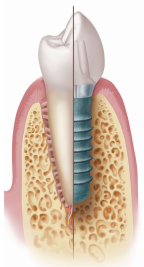

- Replacement of the tooth root
- Help prevent bone loss
- Help preserve adjacent teeth
- Allow patients to bite and chew naturally
- Help patients speak naturally and feel like themselves
- Help patients feel more attractive

DentalWorks

© 2018 Joseph Krajekian DMD, MD

9

Dental implants replace the tooth root

The conventional treatment replaces the crown of the missing tooth, not the root.

A dental implant replaces both the crown and root.

DentalWorks

© 2018 Joseph Krajekian DMD, MD

10

Dental implants replace the tooth root

Healthy tooth roots transfer forces, which:

- Help to maintain position of adjacent teeth
- Help to maintain jaw bone

DentalWorks

© 2018 Joseph Krajekian DMD, MD

11

Dental implants help prevent bone loss

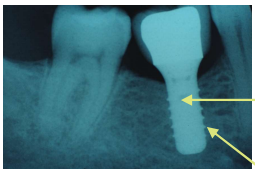

Tooth root replacement

Jawbone forms bond with the dental implant

Osteointegration

DentalWorks

© 2018 Joseph Krajekian DMD, MD

12

Dental implants help preserve surrounding teeth

DentalWorks

© 2018 Joseph Krajekian DMD, MD

13

Dental implants may help maintain facial contours

The collapse of facial contours resulting from bone loss can severely affect your appearance.

Dental implants can help maintain the bone that is crucial to maintaining facial contours.



DentalWorks

© 2018 Joseph Krajekian DMD, MD

14

Dental implants allow patients to bite and to chew naturally

Over 97% of patients surveyed replied that their Straumann dental implants **function very well** and that they could **chew on them well.**

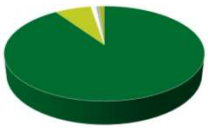

DentalWorks

© 2018 Joseph Krajekian DMD, MD

15

Consequence of single tooth extraction

DentalWorks

© 2018 Joseph Krajekian DMD, MD

16

Consequence of full mouth teeth extraction

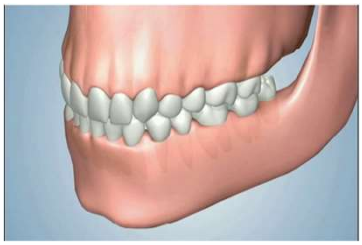

DentalWorks

© 2018 Joseph Krajekian DMD, MD

17

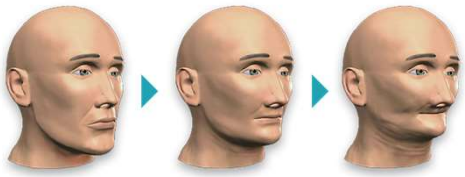

DentalWorks

© 2018 Joseph Krajekian DMD, MD

18

Conventional options for tooth replacement

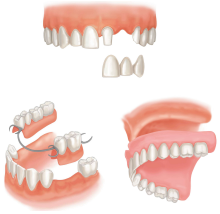

- Bridge work
- Flipper/Partial denture
- Full denture
- No treatment

DentalWorks © 2018 Joseph Krajekian DMD, MD

19

Dental implants replace the tooth root

The conventional treatment replaces the crown of the missing tooth, not the root.

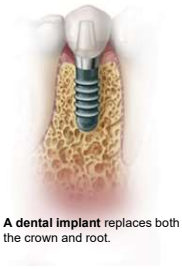

A dental implant replaces both the crown and root.

DentalWorks © 2018 Joseph Krajekian DMD, MD

20

Consequence of 3 Unit Bridge

DentalWorks © 2018 Joseph Krajekian DMD, MD

21

Dental implants help prevent bone loss

Bone loss beneath bridgework

DentalWorks © 2018 Joseph Krajekian DMD, MD

22

Dental implants help preserve surrounding teeth

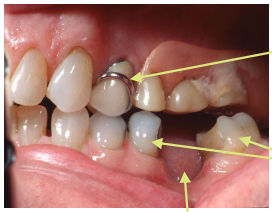

Clasps can compromise existing dentition

Shifting of adjacent teeth

Severe bone loss

DentalWorks © 2018 Joseph Krajekian DMD, MD

23

Dental implants help preserve surrounding teeth

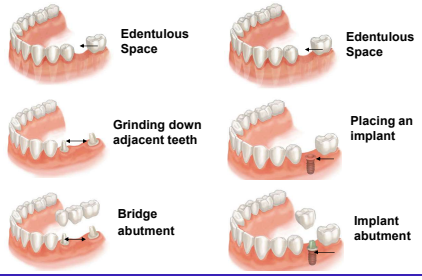

DentalWorks © 2018 Joseph Krajekian DMD, MD

24

Dental implants timing without bone grafting

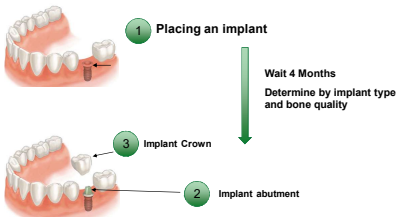

DentalWorks

© 2018 Joseph Krajekian DMD, MD

25

Incorporating Dental Implants?

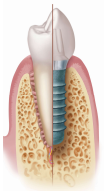

26

Incorporating dental implants into your practice

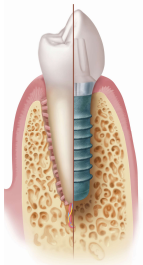

- Start by Initial consultation
- Access availability of bone
  - Width and height
- Determine number of implants and need for grafting (determined by general dentist in coordination of surgeon)

DentalWorks

© 2018 Joseph Krajekian DMD, MD

27

Implant Teamwork

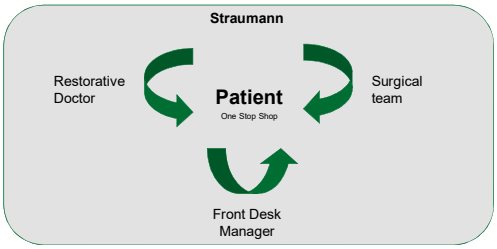

DentalWorks

© 2018 Joseph Krajekian DMD, MD

28

Medical Evaluation

29

Medical Evaluation

- Coronary Heart Disease
  - What do you consider safe parameters to treat patient?
  - History of Myocardial infraction, Hypertension?
  - History of CABG – do you premedicate?
- Diabetes Mellitus
  - Glucose control status assessment and impact on Implant success
- Thyroid disease
  - What do you consider safe parameters to treat patient?

DentalWorks

© 2018 Joseph Krajekian DMD, MD

30

Medical Evaluation

- Adrenal Gland Disorder
  - Stress steroid management
  - Steroid effect on implant osteointegration
- Pregnancy
  - Indication vs contra-indication ?
- Liver Disease (Cirrhosis)
  - Indication vs contra-indication ?

DentalWorks © 2018 Joseph Krajekian DMD, MD

31

Medical Evaluation

- Osteoperosis
  - Effect on osteointegration.
- Hyperparathyroid disease
  - Indication vs contra-indication ?
- Paget Disease
  - Indication vs contra-indication ?

DentalWorks © 2018 Joseph Krajekian DMD, MD

32

Medical Evaluation

- Autoimmune Disease
  - Sjogren's Sydrome
  - Systemic Lupus Erythematosus
  - Rheumatoid Arthritis
  - Human Immunodeficiency Virus

DentalWorks © 2018 Joseph Krajekian DMD, MD

33

Medical Evaluation

- Aspirin + Plavix
  - Should you discontinue? How long?
  - ADA / AAOMS position statement.
- Coumadin
  - Vitamin dependent factors, INR test value.
  - ADA / AAOMS position statement.
- Herbal Supplements / Energy Drinks
  - Bleeding risk / arrhythmias / blood pressure

DentalWorks © 2018 Joseph Krajekian DMD, MD

34

Medical Evaluation

- Smoking
  - Effect of tobacco
    1. Decrease blood flow (vasoconstriction)
    2. Tissue hypoxia
    3. Collagen deposition
    4. Prostacyclin formation
    5. Increases platelet aggregation
    6. Polymorphonuclear neutrophil dysfunction
    7. Increases fibrinogen
    8. Blood viscosity
    9. Systemic increase in epinephrine, norepinephrine
- Radiation
  - Effect on osteointegration'

DentalWorks © 2018 Joseph Krajekian DMD, MD

35

Implant Pharmacology

36

Implant Pharmacology

- Prophylactic
  - Single dose is adequate in healthy patients
  - Chlorhexidine use
- Therapeutic
  - Be aware of adverse reaction about 7%

HIGH	MEDIUM	LOW
Ampicillin	Penicillin	Tetracyclines
Amoxicillin	Erythromycin	Metronidazole
Cephalosporin	Quinolones	Vancomycin
Clindamycin		

DentalWorks

© 2018 Joseph Krajekian DMD, MD

37

Implant Pharmacology

- Post-op infection in implant surgery has significant effect on dental implant success and bone grafting
- Post-op antibiotics significantly disease risk of infection for dental implants
  - Amoxicillin: the usual drug of choice If allergic,
  - Cephalexin (nonanaphylactic allergy to penicillin)
  - Clindamycin (anaphylactic allergy to penicillin)

For sinus involvement procedures

- Augmentin
- Levaquin (if history of recent use of antibiotics [within 4 weeks])

Box 21-3 Microorganisms Most Commonly Associated with Peri-Implant Complications

- *Staphylococcus* spp.
- *Actinomyces* spp.
- Surface translocating bacteria
- *Wolinella* spp.
- *Capnocytophaga* spp.
- *Fusobacterium* spp.
- *Entamoeba gingivalis*
- Motile rods
- Fusiforms
- Spirochetes
- Enteric gram-negative bacteria
- *Candida albicans*

DentalWorks

© 2018 Joseph Krajekian DMD, MD

38

Implant Bone Density

39

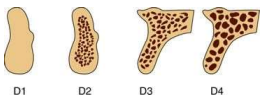

BONE DENSITY	DESCRIPTION	TACTILE ANALOG	TYPICAL ANATOMICAL LOCATION
D1	Dense cortical	Oak or maple wood	Anterior mandible
D2	Porous cortical and coarse trabecular	White pine or spruce wood	Anterior mandible
			Posterior mandible
			Anterior maxilla
D3	Porous cortical (thin) and fine	Balsa wood	Anterior maxilla
			Posterior maxilla
	trabecular		Posterior mandible
D4	Fine trabecular	Styrofoam	Posterior maxilla

DentalWorks

© 2018 Joseph Krajekian DMD, MD

40

Bone Density Distribution

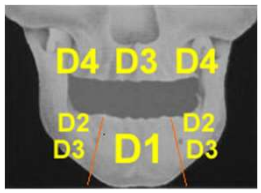

DentalWorks

© 2018 Joseph Krajekian DMD, MD

41

Bone Density D1

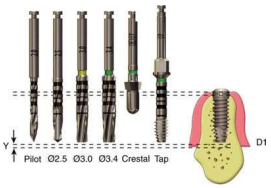

DentalWorks

© 2018 Joseph Krajekian DMD, MD

42

Bone Density D2

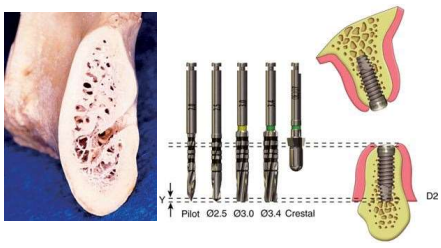

DentalWorks

© 2018 Joseph Krajekian DMD, MD

43

Bone Density D3

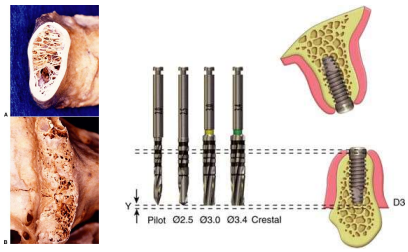

DentalWorks

© 2018 Joseph Krajekian DMD, MD

44

Bone Density D4

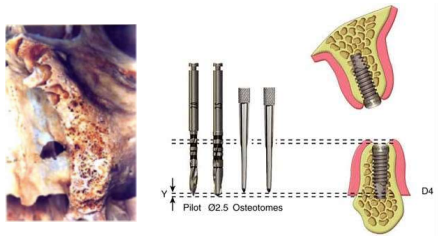

DentalWorks

© 2018 Joseph Krajekian DMD, MD

45

Bone Density Study

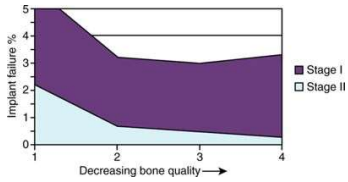

D1 Bone
Highest Failure Rate

D4 Bone
2nd highest Failure Rate

The Dental Implant Research Group represents 33 different hospitals that place dental implants. The highest surgical failure rate was quality 1 bone, followed by quality 4 bone. The fewest surgical failures were observed in quality 3 bone

DentalWorks

© 2018 Joseph Krajekian DMD, MD

46

Osteotomy Preparation

	OVER-HEATING	TIME	FINAL SIZE DRILLS, NUMBER, SPEED	CREST MODULE DRILL	TAP	INSERTION	HEALING	STAGE II UNCOVERY
D1	++++Highest risk	1 sec in, 2 sec out "bone dance"	Increase number in sequence. Increase speed 2500 rpm	Yes	Yes (hand ratchet)	Above crest; hand piece unthread 1/2 turn	Lamellar bone; decreased blood supply	3 to 4 Highest risk months (immediate load)
D2	++ High risk	5 sec out of 10 sec in bone	Manufacturer's protocol; 1500-2500 rpm	Yes	Optional hand piece	At or above crest; hand piece	Ideal	4 months
D3	+		Decrease final size; decrease number; 2500 rpm	No	Optional hand piece	At or below crest; handpiece	Excellent blood supply; risk of early movement(+)	5 months (rough surface implants)
D4			Minimum number; decrease final size; osteotome	No	No	Below crest; hand piece	Risk of micromove-ment (+++)	6 months (rough surface implants)

DentalWorks

© 2018 Joseph Krajekian DMD, MD

47

Implant Placement Based on Bone Density

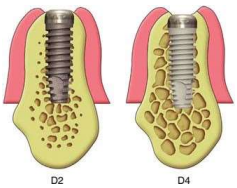

DentalWorks

© 2018 Joseph Krajekian DMD, MD

48

Anatomical Consideration

49

Patient Selection

Bone availability

- Width – accessed clinically
- Height – accessed radio

Various bone grafting procedures available to create bone to allow denta placement.

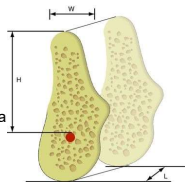

DentalWorks

© 2018 Joseph Krajekian DMD, MD

50

Anatomical Considerations

Structure	Minimum Required Distance Between Implant and Indicated Structure
Buccal plate	1 mm
Lingual plate	1 mm
Maxillary sinus	1 mm
Nasal cavity	1 mm
Incisive canal	Avoid midline maxilla
Interimplant distance	3 mm between outer edge of implants
Inferior alveolar canal	2 mm from superior aspect of bony canal
Mental nerve	5 mm from anterior of bony foramen
Inferior border	1 mm
Adjacent natural tooth	1 mm

DentalWorks

© 2018 Joseph Krajekian DMD, MD

51

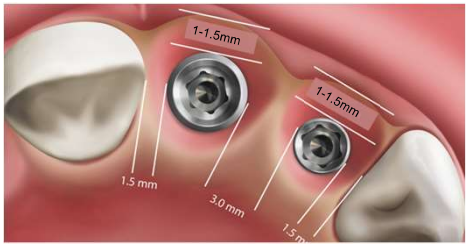

DentalWorks

© 2018 Joseph Krajekian DMD, MD

52

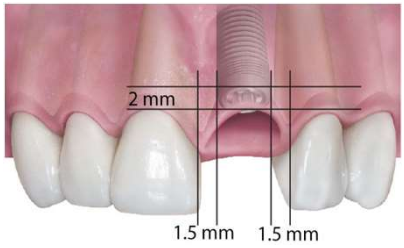

DentalWorks

© 2018 Joseph Krajekian DMD, MD

53

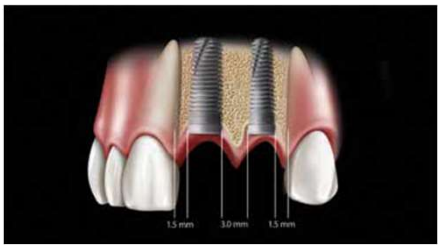

DentalWorks

© 2018 Joseph Krajekian DMD, MD

54

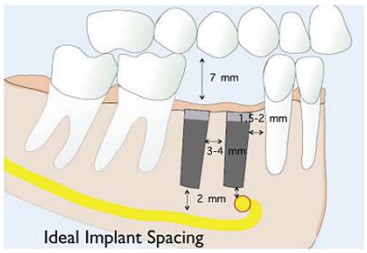

DentalWorks © 2018 Joseph Krajekian DMD, MD

55

Anatomical Considerations

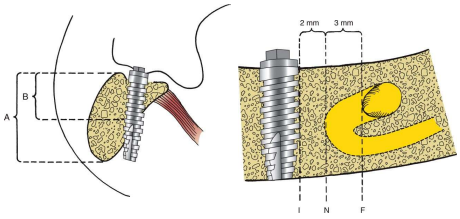

DentalWorks © 2018 Joseph Krajekian DMD, MD

56

Bone Grafting Procedures

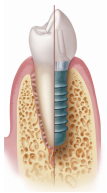

57

Bone Grafting

Socket/ridge Preservation
- Performed at time of extraction

Sinus Lift
- Adds bone height to posterior maxilla

Onlay Graft (via block graft/ split ridge/mesh)
- Adds bone width and height to maxilla and mandible

PRP (platelet rich plasma)
- Filtered platelets from patient's blood containing growth factures to stimulate bone growth

BMP (bone morphogenic protein)
- Synthetic protein that generated bone

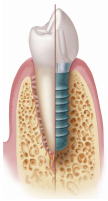

DentalWorks © 2018 Joseph Krajekian DMD, MD

58

Socket / Ridge Preservation

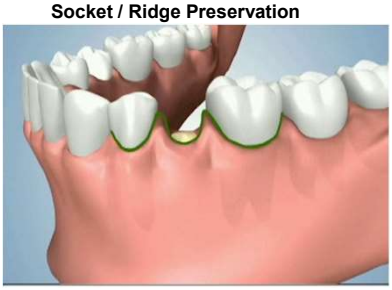

DentalWorks © 2018 Joseph Krajekian DMD, MD

59

Socket / Ridge Preservation with Immediate Implant Placement

DentalWorks © 2018 Joseph Krajekian DMD, MD

60

Sinus Lift

DentalWorks © 2018 Joseph Krajekian DMD, MD

61

Onlay Graft (Block Graft from Chin)

Block / onlay Graft – from chin

DentalWorks © 2018 Joseph Krajekian DMD, MD

62

Ridge Augmentation Technique

DentalWorks © 2018 Joseph Krajekian DMD, MD

63

Bone Grafting and Implant Timing

Socket Preservation
- Wait 3 months prior to implant placement

Sinus Lift
- If implant was not placed at time of grafting then need to wait 6 months prior to implant placement

All other techniques Onlay/ BMP/ PRP
- Need to wait 6 months prior to implant treatment.

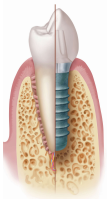

DentalWorks © 2018 Joseph Krajekian DMD, MD

64

Treatment Planning

65

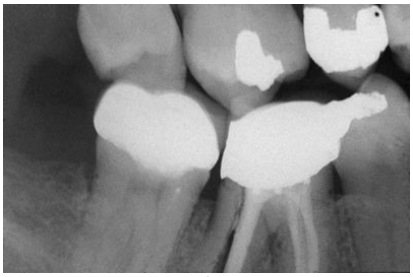

The most common cause of single-tooth loss is endodontic failure or fracture after endodontic therapy.

DentalWorks © 2018 Joseph Krajekian DMD, MD

66

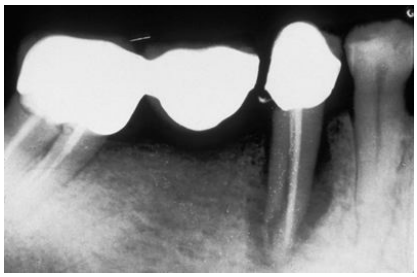

DentalWorks © 2018 Joseph Krajekian DMD, MD

67

Contraindications for Use of Fixed Partial Dentures

1. Poor abutment teeth support
2. Inadequate hard or soft tissue (or both) in esthetic regions (pontic contour)
3. Patient will not allow preparation of adjacent teeth (patient desire)
4. Young patients with large pulp horns in clinical crowns

DentalWorks © 2018 Joseph Krajekian DMD, MD

68

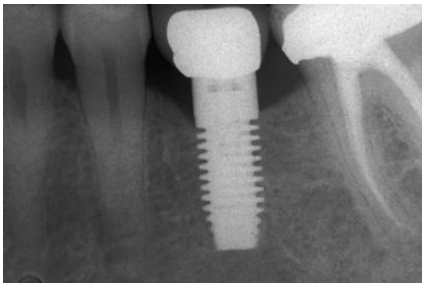

A single-tooth implant is usually the best treatment option to replace a posterior missing tooth. A 10-year report by Priest indicated the posterior single-tooth implant was more than 97% successful.

DentalWorks © 2018 Joseph Krajekian DMD, MD

69

Contraindications for a Posterior Single-Tooth Implant versus Indications for a Posterior Three-Unit FPD

LOCAL CONTRAINDICATIONS FOR A POSTERIOR SINGLE-TOOTH IMPLANT	INDICATIONS FOR A POSTERIOR THREE-UNIT FPD
Inadequate bone volume	Indequate bone volume
Faciopalatal <5 mm	Inadequate intratooth space <6.5 mm (may also use two unsplinted crowns)
Mesiodistal <6.5 mm for a >3.5-mm-diameter implant	Lack of intratooth bone height
Moderate to advanced mobility of two to four adjacent teeth	Adjacent teeth are mobile
Limited time for patient treatment	Reduced time of treatment

DentalWorks © 2018 Joseph Krajekian DMD, MD

70

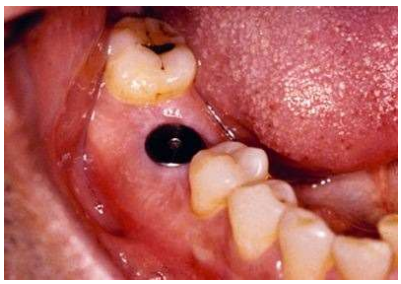

DentalWorks © 2018 Joseph Krajekian DMD, MD

71

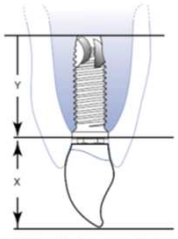

FIGURE 14-11 *Ideal crown-to-implant ratio occurs when X ≤ Y.*

DentalWorks © 2018 Joseph Krajekian DMD, MD

72

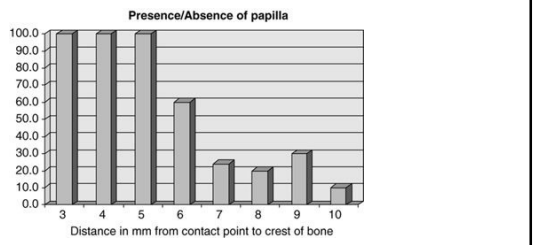

The distance from the interproximal contact to the crest of bone with natural teeth most often measures 5, 6, or 7 mm.

DentalWorks

© 2018 Joseph Krajekian DMD, MD

73

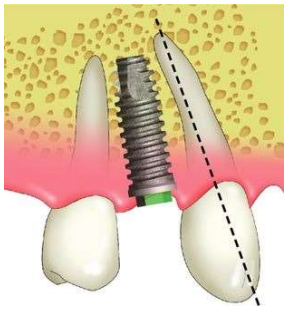

DentalWorks

© 2018 Joseph Krajekian DMD, MD

74

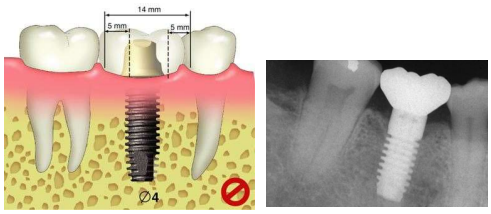

DentalWorks

© 2018 Joseph Krajekian DMD, MD

75

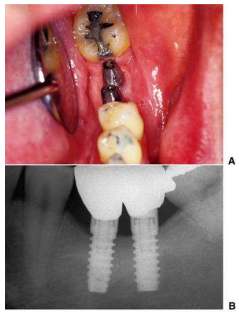

DentalWorks

© 2018 Joseph Krajekian DMD, MD

76

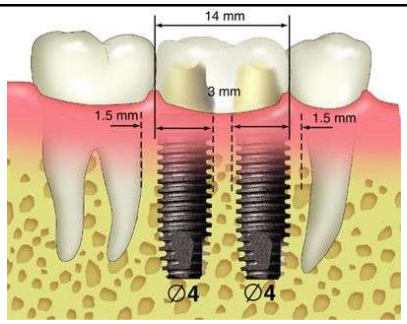

DentalWorks

© 2018 Joseph Krajekian DMD, MD

77

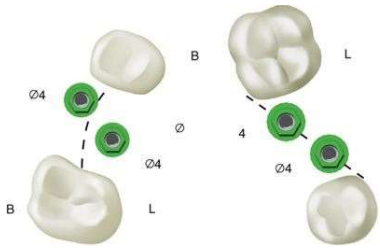

DentalWorks

© 2018 Joseph Krajekian DMD, MD

78

DentalWorks © 2018 Joseph Krajekian DMD, MD

79

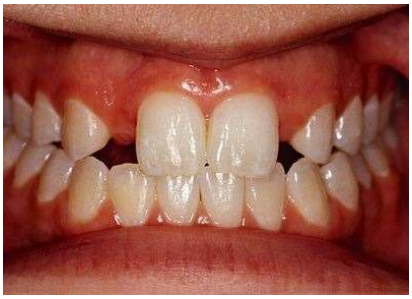

DentalWorks © 2018 Joseph Krajekian DMD, MD

80

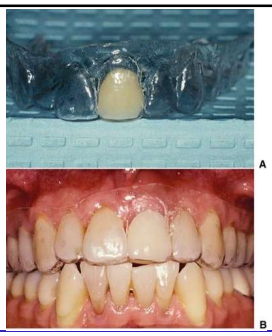

DentalWorks © 2018 Joseph Krajekian DMD, MD

81

Contraindications for Resin-Retained Fixed Partial Dentures

1. Thin enamel on abutment teeth
2. Mobile abutment or abutments
3. Vertical overlap
4. Bruxism
5. Anterior diastemata
6. Short clinical crown
7. Poor occlusal relationship

DentalWorks © 2018 Joseph Krajekian DMD, MD

82

Maxillary Anterior Single-Tooth Replacement Influencing Factors of Treatment

1. Patient compliance and patient fear
2. Patient desires
3. Treatment time
4. Consequence of failure—potential damage to adjacent teeth
5. Cost
6. Patient's age
7. Esthetics
8. Adjacent tooth mobility
9. Crown height and occlusal relationship
10. Mesiodistal space at crown and bone level
11. Available bone height
12. Available bone width (buccolingual)
13. Soft tissue drape type—surrounding gingival tissues
14. Transitional prosthesis

DentalWorks © 2018 Joseph Krajekian DMD, MD

83

DentalWorks © 2018 Joseph Krajekian DMD, MD

84

DentalWorks © 2018 Joseph Krajekian DMD, MD

85

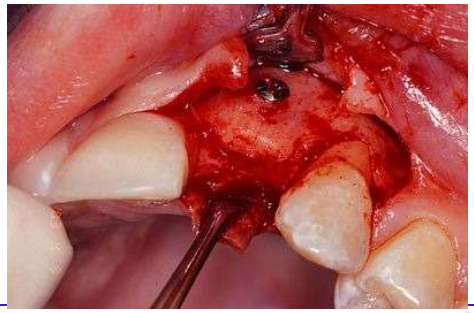

DentalWorks © 2018 Joseph Krajekian DMD, MD

86

Local Contraindications for the Anterior Single-Tooth Implant

1. Inadequate bone volume
   a. Faciopalatal (<5.5 mm)
   b. Mesiodistal (<6 mm for a 3.2-mm implant to allow 1.5 to 2 mm from adjacent roots; varies in function of tooth replaced)
   c. Height (< 9 mm)
2. Inadequate crown height
3. Mobility of two to four adjacent teeth > +1

DentalWorks © 2018 Joseph Krajekian DMD, MD

87

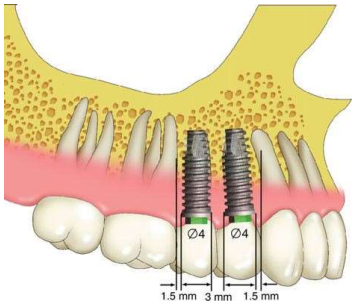

DentalWorks © 2018 Joseph Krajekian DMD, MD

88

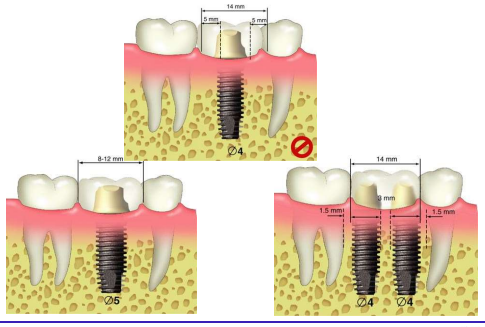

DentalWorks © 2018 Joseph Krajekian DMD, MD

89

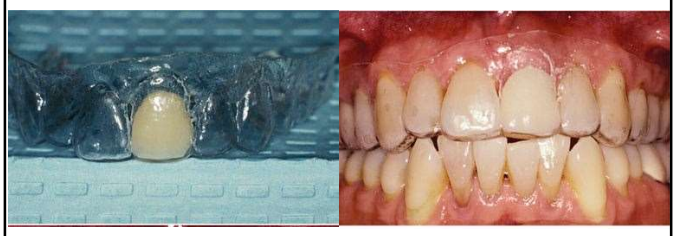

DentalWorks © 2018 Joseph Krajekian DMD, MD

90

KEY IMPLANT POSITIONS

DentalWorks © 2018 Joseph Krajekian DMD, MD

91

Guidelines for Key Implant Positions

- No cantilevers
- No three adjacent pontics
- Canine-molar rule
- Arch dynamics

DentalWorks © 2018 Joseph Krajekian DMD, MD

92

Guidelines for Key Implant Positions

- Three adjacent pontics should not be designed in the prosthesis.
- The canine and first molar sites are key positions, especially when adjacent teeth are missing.
- An arch is divided into five segments. When more than one segment of an arch is being replaced, a key implant position is at least one implant in each segment.

DentalWorks © 2018 Joseph Krajekian DMD, MD

93

No cantilevers

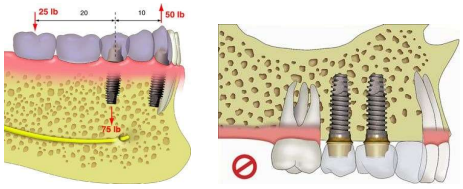

DentalWorks © 2018 Joseph Krajekian DMD, MD

94

No cantilevers

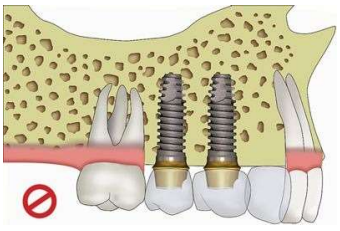

DentalWorks © 2018 Joseph Krajekian DMD, MD

95

Terminal abutments are key implant positions

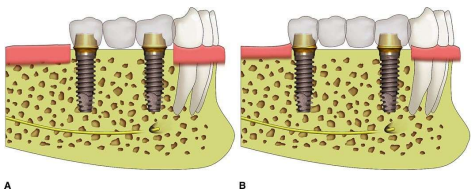

DentalWorks © 2018 Joseph Krajekian DMD, MD

96

No Three Adjacent Pontics

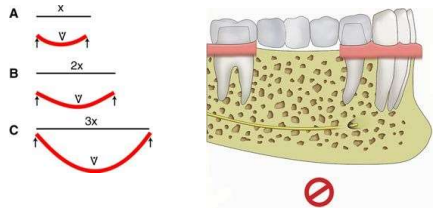

DentalWorks © 2018 Joseph Krajekian DMD, MD

97

No Three Adjacent Pontics

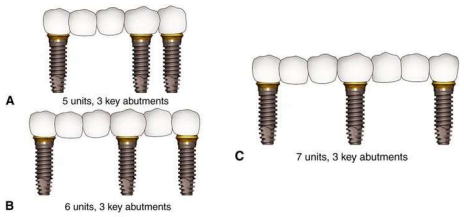

DentalWorks © 2018 Joseph Krajekian DMD, MD

98

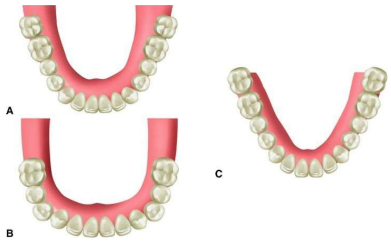

DentalWorks © 2018 Joseph Krajekian DMD, MD

99

DentalWorks © 2018 Joseph Krajekian DMD, MD

100

DentalWorks © 2018 Joseph Krajekian DMD, MD

101

DentalWorks © 2018 Joseph Krajekian DMD, MD

102

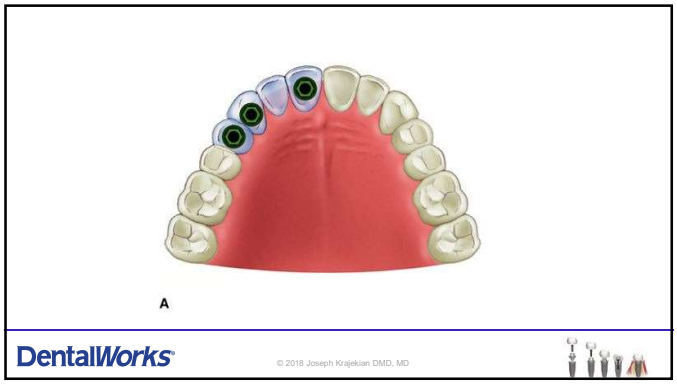

103

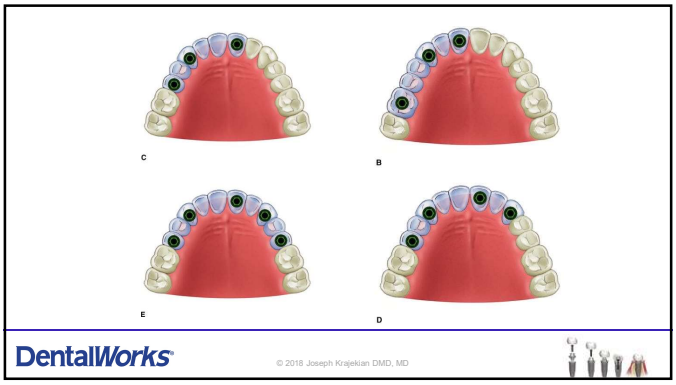

104

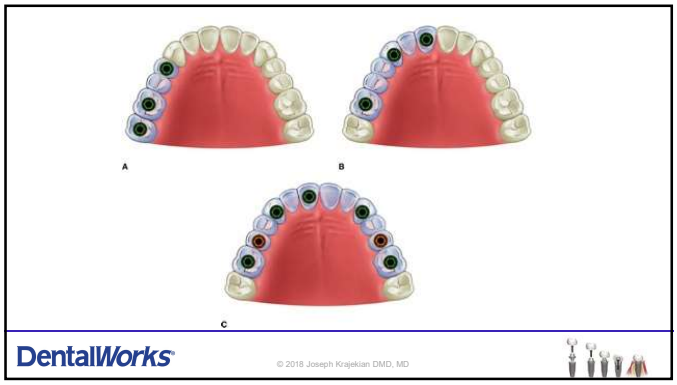

105

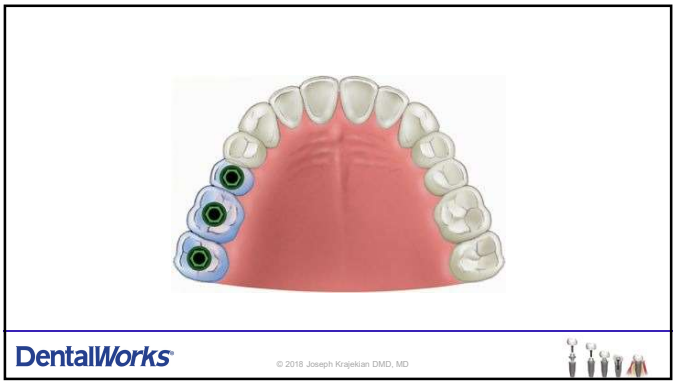

106

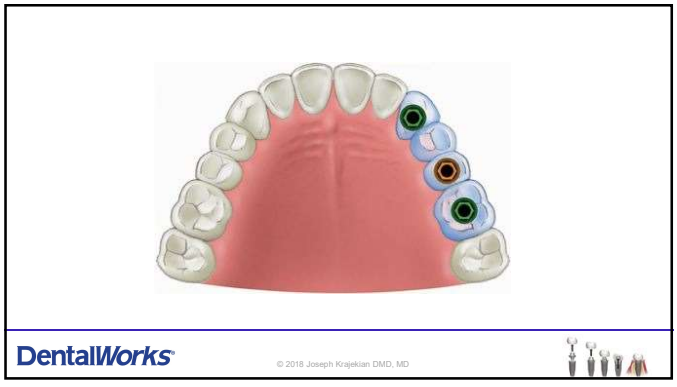

107

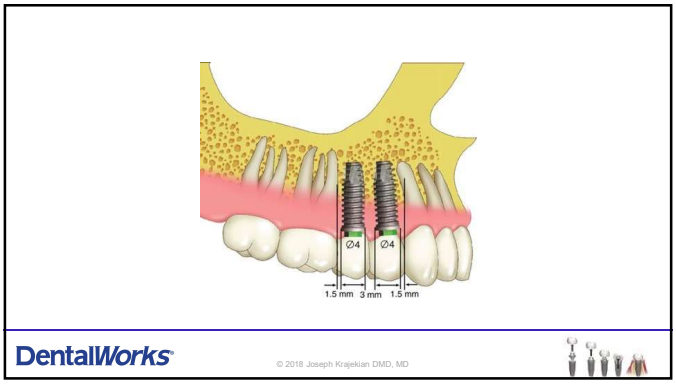

108

Screw Vs Cement

Table 14-2 Screw Retention versus Cement Retention

Advantages		*Disadvantages*	
Screw Retention	*Cement Retention*	*Screw Retention*	*Cement Retention*
Retrievability	Esthetic	Implant placement critical	Cement removal subgingivally
Porcelain emergence	Angle correction possible	Screw access channel visible	Abutment selection critical in anterior
Cost effective	Less bulk of restorationin anterior areas	Deep channels should be sealed	Provisional restoration needed in anterior
Elimination of cement retrieval	Built in load indicator by two interfaces		Cost factor with abutment/restoration
			Problematic retrievability

DentalWorks © 2018 Joseph Krajekian DMD, MD

109

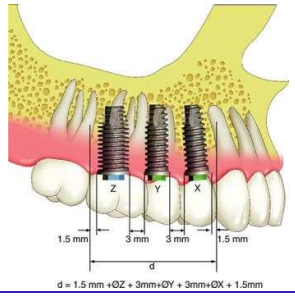

DentalWorks © 2018 Joseph Krajekian DMD, MD

110

Complications

111

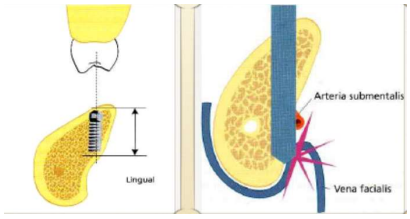

DentalWorks © 2018 Joseph Krajekian DMD, MD

112

BLEEDING SITE DURING IMPLANT OSTEOTOMY	ARTERIES	TREATMENT
Posterior mandible	Mylohyoid	Finger pressure at the site
Middle lingual of mandible	Submental	Surgical ligation of facial and lingual arteries
Anterior lingual of mandible	Terminal branch of sublingual or submental	Compression, vasoconstriction, cautery, or ligation
Invading the mandibular canal	Inferior alveolar artery	Bone graft

DentalWorks © 2018 Joseph Krajekian DMD, MD

113

Criteria for Evaluation of Successful Implants at Stage II Uncovery

- Rigid fixation
- Absence of crestal bone loss
- Absence of pain
- Adequate zone of keratinized gingiva
- Sulcus depth 4 mm
- Absence of inflammation
- Proper hard and soft tissue contour
- Prosthetic abutment allows implant loading under physiologic conditions

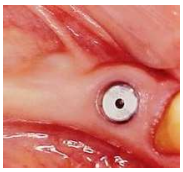

DentalWorks © 2018 Joseph Krajekian DMD, MD

114

Implant Failure Terminology

TYPE OF FAILURE	TIMING
Surgical	At surgery
Osseous healing failure	Between stages I and II
Early loading	Abutment placement to first year
Intermediate	First-year loading to 5 years
Late	5 to 10 years
Long term	>10 years

DentalWorks © 2018 Joseph Krajekian DMD, MD

115

GROUP	MANAGEMENT	CLINICAL CONDITIONS
I. Success (optimum health)	Normal maintenance	No pain or tenderness upon function 0 mobility <2 mm radiographic bone loss from initial surgery Probing depth <5 mm No exudate history
II. Survival (satisfactory health)	Reduction of stresses Shorter intervals between hygiene appointments Gingivoplasty Yearly radiographs	No pain 0 mobility 2-4 mm radiographic bone loss Probing depth 5 to 7 mm No exudate history
III. Survival (compromised health)	Reduction of stresses Drug therapy (antibiotics, chlorhexidine) Surgical reentry and revision Change in prosthesis or implants	No pain upon function 0 mobility Radiographic bone loss > 4 mm Probing depth > 7 mm May have exudate history
IV. Failure (clinical or absolute failure)	Removal of implant	Any of the following: Pain upon function Mobility Radiographic bone loss >1/2 length of implant Uncontrolled exudate No longer in mouth

From International Congress of Oral Implantologies, Consensus Conference, Pisa, Italy, 2007.

DentalWorks © 2018 Joseph Krajekian DMD, MD

116

Resolution of Bone Loss at Uncovery

DEFECT	MANAGEMENT	OPTIONS
Vertical <3 mm	Osteoplasty	Convert into horizontal defect by leveling off bone
Vertical >3 mm	Less than half of implant height More than half of implant height	Graft with autogenous bone wedge or membrane if deep defect Remove implant
Horizontal	Less than half of implant height More than half of implant height	Position soft tissue apically; graft autogenous bone Remove implant

DentalWorks © 2018 Joseph Krajekian DMD, MD

117

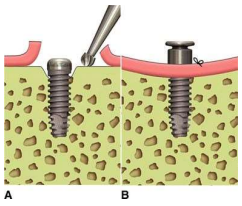

DentalWorks © 2018 Joseph Krajekian DMD, MD

118

How to refer an Implant to OS

119

DentalWorks
"The way dental should work"
Oral & Maxillofacial Surgery Referral Form

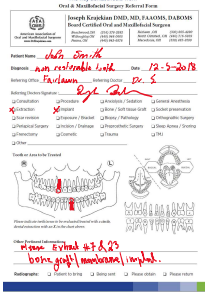

Patient Needing Individual Implants

Evaluate the patient clinically
May sure patient has a panorex

Patient Needing Extraction (all Surgical)

Surgeon
1) Extraction / Bone / Membrane
2) Dental Implants
3) Uncovering (stage II)

Dentist
4) Abutment
5) Crown

DentalWorks © 2018 Joseph Krajekian DMD, MD

120

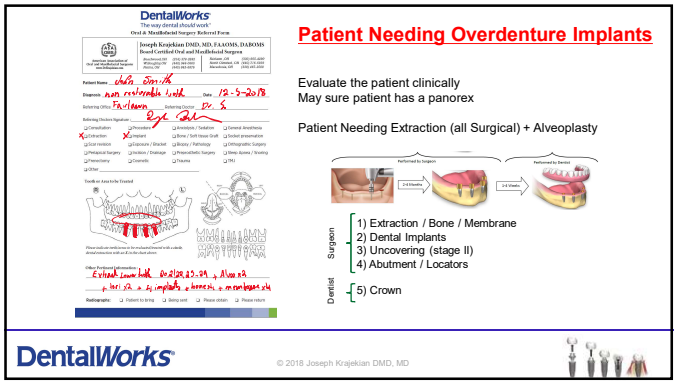
DentalWorks
Patient Needing Overdenture Implants
Evaluate the patient clinically
May sure patient has a panorex
Patient Needing Extraction (all Surgical) + Alveoplasty
Surgeon
1) Extraction / Bone / Membrane
2) Dental Implants
3) Uncovering (stage II)
4) Abutment / Locators
Dentist
5) Crown
DentalWorks
© 2018 Joseph Krajekian DMD, MD

121

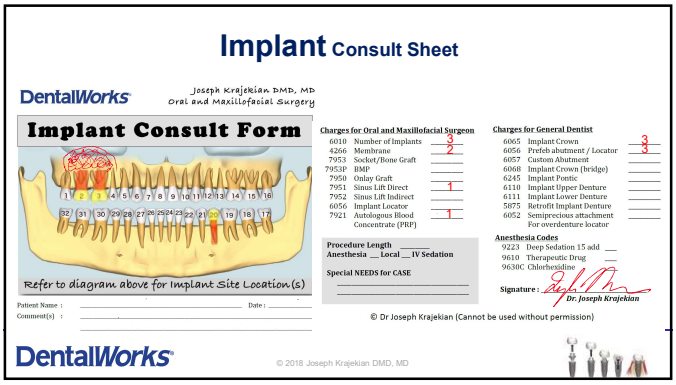
Implant Consult Sheet
DentalWorks
Joseph Krajekian DMD, MD
Oral and Maxillofacial Surgery
Implant Consult Form
Refer to diagram above for Implant Site Location(s)
Charges for Oral and Maxillofacial Surgeon
Charges for General Dentist
Procedure Length
Anesthesia __ Local __ IV Sedation
Special NEEDS for CASE
Signature :
Dr. Joseph Krajekian
© Dr Joseph Krajekian (Cannot be used without permission)
DentalWorks
© 2018 Joseph Krajekian DMD, MD

122


DentalWorks
DentalWorks
© 2018 Joseph Krajekian DMD, MD

123